

## RENAL ARTERY DIMENSIONS AND VARIATION ON CT ANGIOGRAM: A CROSS-SECTIONAL STUDY

Om Biju Panta<sup>1</sup>, Shahjan Raj Giri<sup>1</sup>, Bibek Gurung<sup>1</sup>, Vivek Dhakal<sup>1</sup>, Ram Kumar Ghimire<sup>1</sup><sup>1</sup> Department of Radiology; Nepal Medciti Hospital, Lalitpur, Nepal

**Date of Submission** : Jun 11, 2021  
**Date of Acceptance** : Jan 10, 2022  
**Date of Publication** : Feb 15, 2022

**\*Correspondence to:**

Dr. Om Biju Panta, MD  
 Department of Radiology, Nepal Medciti Hospital,  
 Lalitpur, Nepal  
 Email- bijupanta@yahoo.com, Ph- 9842877382

**ORCID ID:** 0000-0002-0140-1506

**Citation:**

Panta OB, Giri SR, Gurung B, Dhakal V, Ghimire RK.  
 Renal artery dimensions and variation on CT an-  
 giogram: a cross-sectional study. Medphoenix.  
 2021;6(2):25-29

**DOI:** 10.3126/medphoenix.v6i2.38371

**Conflict of interest:** None, **Funding:** None

**Publisher:** National Medical College Pvt. Ltd.  
**MedPhoenix - Journal of National Medical College**  
**(JNMC); 2021,6(2), available at www.jnmc.com.np**

ISSN:2631-1992 (Online); ISSN:2392-425X (Print)



This work is licensed under a Creative  
 Commons Attribution 4.0 International  
 License.

**ABSTRACT**

**Introduction:** A knowledge of renal artery dimension is necessary for characterizing the physiological change as well as pathological process undergoing in the renal artery likely stenosis, ectasia, or aneurysm. This study aims to explore the anatomy of the renal artery with regards to its dimension, relation, and branching and identify the common anatomical variation.

**Materials and Methods:** The study was a retrospective hospital record-based study conducted during the period of one year from 2019 January to 2019 December. All abdominal CT angiograms were reviewed for renal artery anatomy and variation. Abnormal Abdominal CT angiograms were excluded from the study. Normal anatomy, dimensions, and variation of renal vasculature were assessed.

**Results:** A total of 110 patients included the inclusion criteria and was included in the study. The renal length and size of the renal artery were significantly larger on the left side. The renal artery diameter showed positive correlation with renal length ( $r = 0.432$ ;  $p < 0.001$ ). No variation of the renal size of renal artery diameter was however noted with sex. Supernumerary arteries were seen in 33(30%) patients. The optimum cut-off value of renal artery diameter for predicting accessory renal artery was 5.35 or less which yielded a sensitivity of 75% and specificity of 70%. (AUC-0.79;  $p < 0.001$ ). When 4.15 mm was taken as cut-off, the specificity increased to 96% with a marked reduction in sensitivity to 3.6%.

**Conclusion:** Renal artery diameter is dependent on laterality, kidney size, and presence of accessory artery and independent of sex.

**Keywords:** angiography; computed tomography; renal artery; renal artery diagnostic imaging.

**INTRODUCTION**

Advances in cross sectional imaging have revolutionized our understanding of anatomy and normal variations. The knowledge of anatomical variation in the particular patient helps to plan the surgical procedure in least invasive way reducing complications. Computed tomography (CT) angiography is one of the most utilized noninvasive modality to define the vascular supply, relation with major vascular structure, and define and identify the vascular variation in preoperative planning.<sup>1</sup> The understanding of renal artery anatomy and variation is a must for planning the nephrectomy and renal transplantation and enlightens the surgeon to avoid compromising the safety of the surgical procedure.<sup>2</sup> CT angiography study of the donor and recipient is a routine study in current practice before renal transplantation.<sup>3</sup> A knowledge of renal artery dimension is necessary for characterizing the physiological change as well as pathological process undergoing in the renal artery likely stenosis, ectasia or aneurysm.<sup>1</sup> Its also aids the endovascular and laparoscopic surgeons for preoperative

planning and also is important for development of stents and medical devices.<sup>4</sup> However there is paucity of literature with regards to renal artery dimensions in our country. This study aims to explore the anatomy of renal artery with regards to its dimension, relation and branching and identify the common anatomical variation.

**MATERIALS AND METHODS**

The study was a retrospective hospital record-based study conducted in a Department of Radiology and Imaging at our hospital. Abdominal Aortic angiograms performed during the period of one year from 2019 January to 2019 December were reviewed. All abdominal aortic angiograms were performed in Siemens SOMATOM Definition 128 slice CT scan. CT angiogram was performed after injection of 1ml/kg non-ionic contrast at 5.5 ml/sec followed by saline chase of 20-50 ml at 6ml/min with bolus tracking technique and region of interest placed at the proximal abdominal aorta at the level of celiac trunk. All patients with normal abdominal aortic angiograms

were included in the study. Patients with aneurysm of aorta, renal artery stenosis, or any anomaly of the kidneys were excluded from the study. Normal anatomy, dimensions and variation of renal vasculature were assessed. Measurements were taken using electronic calipers in Siemens Syngo.via software. The renal artery diameter was assessed at the proximal part 10 mm from the ostium in antero-posterior (AP) dimension. Diameter of Aorta was also measured at the level of origin of renal artery in transverse dimension. The distance of renal artery origin from the celiac trunk was assessed. The distance from the renal artery origin to its first branching was also assessed. Data was entered in predesigned proforma and analysis was done by using IBM SPSS 24.0 software. Numeric data are presented as means and standard deviation and nominal data are presented as numbers and percentage. Means were compared using t-test while correlation were calculated using Pearson's correlation coefficient.

## RESULTS

A total of 110 patients included the inclusion criteria and was included in the study. There were 72 (65.5%) males and 38 (34.5%) females. The mean age of the population was  $44.83 \pm 18.35$  years with median of 46 and interquartile range of 26.

The mean length of right kidney was  $10.01 \pm 0.99$  cm and left kidney was  $10.28 \pm 0.97$  cm. The mean diameter of renal arteries, the distance from the celiac trunk and distance from origin to first branching are presented in Table 1. The length of kidney and the mean diameter of renal artery were significantly larger in left side as compared to right ( $P < 0.001$ ). There was significant positive correlation between the size of the kidney and diameter of main renal artery ( $r = 0.432$ ;  $p < 0.001$ ). Branching within 1.5 cm was seen in 15 of 220 (6.81%) renal arteries assessed (Table 2). Both renal arteries origins were at the same level in seven (6.36%) cases, while right renal artery origin was proximal in 82 (74.54%) cases and left renal artery origin was proximal in 21 (19.09%) cases.

Supernumerary arteries were seen in 33 (30%) patients among whom; 23 (20.9%) were male and 10 (9.09%) were female. A total of 48 supernumerary arteries were detected among the 33 patients out of which 31 (64.6%) were on right and 17 (35.4%) were on the left side. Among them 16 (14.5%) patients had supernumerary arteries on the right side, five (4.5%) had on the left side and 12 (10.9%) had bilaterally. (Table 3) Also, 45 (93.7%) were hilar and three (6.2%) were polar. All the polar arteries entered the lower pole of right kidney. No polar artery was seen in the left side. (Table 4) No significant difference in renal artery dimensions ( $p = 0.17, 0.24$ ) was noted between males and females. (Table 5) The diameter of renal artery was significantly different among patients

with supernumerary renal artery and among those with no supernumerary renal arteries ( $p < 0.001$ ). The length of kidney was significantly different among those with supernumerary renal artery and those without in the right kidney ( $p = 0.036$ ), however there was no such statistical difference demonstrated in left kidney ( $p = 0.10$ ). (Table 6) The diagnostic value of main renal artery diameter in predicting the presence of supernumerary renal artery was evaluated using ROC curve. The optimum cut off value for predicting accessory renal artery was 5.35 mm or less which yielded a sensitivity of 75% and specificity of 70%. (AUC-0.79;  $p < 0.001$ ). When 4.15 mm was taken as cut off, the specificity increased to 96% with marked reduction in sensitivity to 3.6%. (Figure 1)

## DISCUSSION

CT angiography is a non-invasive alternative to conventional angiography and also provides a three-dimensional overview of the renal vessels. CT angiography has thus now been the imaging modality for diagnosis and pre-interventional workup, while conventional angiography is only performed when intervention is to be performed in the same setting.<sup>5</sup>

The renal artery diameter in our study was slightly lower than in study done in Nigeria<sup>1</sup> but was similar to study done in North America<sup>4</sup> and Turkey<sup>6</sup>. The larger diameter of Nigerian population might be explained by the larger built of the patients in Nigeria. Left kidney and renal artery diameter were significantly larger than the right in our study. The size of the left kidney is known to be larger than right from previous studies.<sup>7,8</sup> Larger length of the kidney might be the region for a larger size of renal artery on that side for carrying a larger amount of blood to perfuse a larger kidney volume. The size of the kidney and the size of renal artery also show positive correlation in our study supporting the hypothesis.

The size of renal artery did not show significant difference between genders on either side in our study. However, there is variation in published articles in gender difference in renal artery diameter with some reporting statistical difference and many stating no differences.<sup>1,4,9,10</sup> Prehilar branches or early branching of renal artery is defined as artery with length 15 mm or less before first branching<sup>10</sup>. This anatomic variation is important for preoperative mapping of renal transplant donors and is an exclusion criteria for laparoscopic donor nephrectomy.<sup>5</sup> In our study early branching was seen in 6.8% of all renal arteries that is similar to the previously reported incidence of 7-9%<sup>10</sup>. This variation frequently is confused with supernumerary renal artery and should be born in mind while interpreting renal angiogram studies. The origin of renal arteries is usually described as according to the distance from the celiac trunk.<sup>10,11</sup> In our study right renal artery origin was proximal to left

in most cases with few cases with origin at same level and few other with left renal artery proximal to right. The site of origin of renal artery is important in planning the endovascular repair of abdominal aortic aneurysm and the distance between the two renal arteries needs to be taken in consideration for option between a single versus two-chimney procedure during Endovascular Aortic Aneurysm Repair (EVAR) for juxtra renal abdominal aneurysm.<sup>12</sup>

Supernumerary renal artery was common in our study with 30% of all CT angiogram study having at least one supernumerary renal artery. The incidence of two supernumerary renal arteries is however significantly low (<5%). Supernumerary arteries were more commonly noted in right side than left and they were present in bilateral sides in 10% of cases. The incidence and distribution of supernumerary renal artery in our study are similar to study in the past by Satyapal et.al.<sup>13</sup> except the low incidence of supernumerary renal arteries on the left side in our study. However the incidence is quite low as compared to studies by Palmieri et.al.<sup>9</sup> The higher incidence in the study done by Palmieri et.al. is due to inclusion of pre-hilar branches of renal artery as supernumerary renal arteries. The presence of supernumerary renal artery is believed to relate to persistence of mesonephric vessels and might indicate presence of other renal anomalies and ectopic kidneys as well.<sup>14</sup>

Also, the presence of multiple renal arteries increases the complexity of renal surgeries with increased risk of inadvertent injuries and complication, thus a preoperative knowledge of the presence of supernumerary renal artery is very important before major renal surgeries. The renal length and diameter of renal artery is significantly different in patients with supernumerary renal arteries, which has been attempted to use as an indicator for supernumerary renal artery<sup>6</sup>. Even in our study the renal artery diameter was significantly lower in patients with supernumerary renal arteries. However, with regards to renal length statistically significant difference was observed only on right side. According to study done by Aytec et.al.<sup>15</sup> when diameter of a renal artery measured by sonography is 4.65 mm or less, the presence of an accessory renal artery can be established with 80% sensitivity and 80.5% specificity. If the diameter of the main renal artery is 4.15 mm or smaller, the presence of an accessory renal artery is extremely probable, with 98.8% specificity. In our study the optimum cut off value for predicting accessory renal artery was 5.35 mm or less which yielded a sensitivity of 75% and specificity of 70%. (AUC-0.79; p<0.001). When 4.15 mm was taken as cut off, the specificity increased to 96% with marked reduction in sensitivity to 3.6%. The size of renal artery can be useful in

ultrasound Doppler evaluation of renal arteries, a cutoff of less than 5 mm may be useful for indicating need for extensive search of accessory renal arteries during the examination. However, the prediction of supernumerary renal artery with main renal artery diameter alone is not sufficient to be used in clinical practice from the present evidence.

## CONCLUSIONS

Our study had several limitations. Firstly, the study was a hospital record based study performed in limited population, which might not be true representation of the population. The racial and age-related difference of kidney size and renal artery dimensions and variation was not considered. Renal artery diameter is dependent on laterality, kidney size and presence of accessory artery and independent of sex. Accessory renal arteries are relatively common and can be predicted by small main renal artery diameter, however evidence is insufficient to be used in clinical practice. Further studies with renal artery dimension and presence of supernumerary renal artery on can be a useful guide in future to detect presence and pathology of accessory renal artery.

**Acknowledgement:** None

## Table Legends:

**Table 1. Mean diameter, distance from celiac trunk and distance to first branching of renal arteries.**

Parameter	Mean (SD)
Mean Diameter of Right Main Renal Artery (Ap)	5.63±0.91 MM
Mean Diameter of Left Main Renal Artery (Ap)	5.90 ± 0.86 MM
Distance from Celiac Trunk to Right Main Renal Artery	2.64±0.86 CM
Distance from Celiac Trunk to Left Main Renal Artery	3.02±0.66 CM
Distance from Origin to First Branching of Right Renal Artery	3.77±1.39 Cm
Distance from Origin to First Branching Of Left Renal Artery	3.08± 1.06 Cm
Diameter of Aorta at The Level of Renal Artery	1.58± 0.24 Cm

**Table 2. Number of renal arteries with Early Branching**

Early Branching	Number (%) N=110
Branching Within 1.5 Cm of Its Origin	
Left	5(4.5)
Right	10(9.1)
Branching Within 2.0 Cm of Its Origin	
Left	15(13.6)
Right	13(11.8)

**Table 3. Patients with supernumerary renal arteries**

	Number (%)
Number of patients with supernumerary renal artery	33 (30)
Supernumerary artery in right side only	16(14.5)
Supernumerary artery in left side only	5(4.5)
Supernumerary artery bilaterally	12(10.9)
Total number of supernumerary arteries	48
Total supernumerary artery on right	31
Total supernumerary artery on left	17

**Table 4. Types of supernumerary renal arteries**

Type of supernumerary artery	Number (n=48)
<b>Hilar</b>	
Total	45
Right	28
Left	17
<b>Polar</b>	
Total	3
Right	3
Left	0

**Table 5. Comparison of Renal artery dimensions, anatomy and variation among genders.**

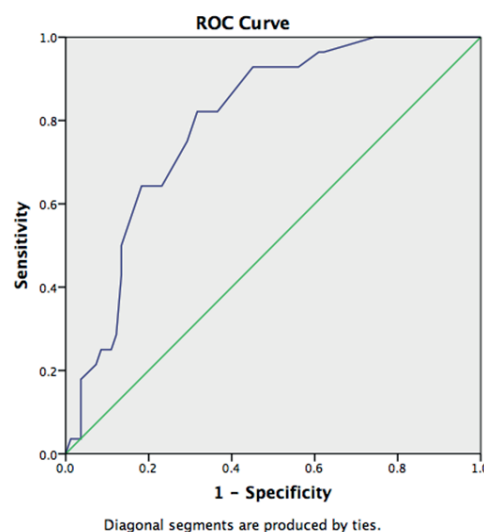
	Male	Female	p-value
Age Mean	46.19 ±19.22	42.23±16.50	0.26
Kidney length (cm)			
Right	10.08±1.00	9.89±0.97	0.34
Left	10.38±0.93	10.09±1.03	0.15
Diameter of main renal artery (mm)			
Right	5.55±0.97	5.78±0.77	0.17
Left	5.84±0.94	6.02±0.69	0.24
Distance of first branching from origin of renal artery (cm)			
Right	3.71±1.25	3.87±1.63	0.59
Left	3.13±1.11	2.98±0.98	0.48
Distance of right renal artery origin from celiac trunk origin (cm)			
Right	2.65±0.80	2.62±0.97	0.84
Left	3.00±0.68	3.06±0.62	0.64
Diameter of aorta at level of renal artery origin (cm)			
Right	1.63±0.25	1.49±0.20	0.003*
Supernumerary Artery			
Right	20	8	0.44
Left	11	6	0.94
Renal vein anomaly	2	1	0.96

\*- significant difference at p<0.05

**Table-6. Association of supernumerary renal artery with renal length and main renal artery diameter.**

	Presence of supernumerary renal artery	Absence of supernumerary renal artery	p-value
<b>Right</b>	(n=28)	(n=82)	
Kidney Length(cm)	10.35±0.70	9.90±1.05	0.036
Main Renal Artery diameter(mm)	4.99±0.58	5.85±0.90	<0.001
<b>Left</b>	(n=17)	(n=93)	
Kidney Length(cm)	9.98±0.75	10.33±0.99	0.10
Main Renal Artery diameter(mm)	5.07 ±0.58	6.05±0.82	<0.001

**Figure Legends:**



**Figure 1. ROC curve for main renal artery diameter and presence of assessor renal artery.**

**REFERENCES**

- Chiaganam NO, Ekpo EU, Egbe NO, Nzotta CC, Okwara KK. Aging and the average diameter of the renal artery using computed tomography angiography (CTA). S Afr Radiogr. 2013;51(1):23-25. [Full Text]
- Arévalo Pérez J, Gragera Torres F, Marín Toribio A, Koren Fernández L, Hayoun C, Daimiel Naranjo I. Angio CT assessment of anatomical variants in renal vasculature: its importance in the living donor. Insights Imaging. 2013;4(2):199-211. [DOI]
- Bruce AU, Lloyd ER, Elliot KF. Three-dimensional Volume-rendered CT Angiography of the Renal Arteries and Veins: Normal Anatomy, Variants, and Clinical Applications. Radio Graphics. 2001;21(2):373-386. [DOI]
- Turba UC, Uflacker R, Bozlar U, Hagspiel KD. Normal renal arterial anatomy assessed by multidetector CT angiography: are there differences between men and women? Clin Anat. Mar 2009;22(2):236-242. [DOI]

5. Hazirolan T, Öz M, Türkbey B, Karaosmanoglu AD, Oguz BS, Canyigit M. CT angiography of the renal arteries and veins: normal anatomy and variants. *Diagn Interv Radiol.* 2011;17(1):67. [[Full Text](#)]
6. Ramadan SU, Yigit H, Gökharman D, et al. Can renal dimensions and the main renal artery diameter indicate the presence of an accessory renal artery? A 64-slice CT study. *Diagn Interv Radiol.* 2011;17(3):266. [[Full Text](#)]
7. Harmse WS. Normal variance in renal size in relation to body habitus. *S Afr J Radiol.* 2011;15(4). [[DOI](#)]
8. Glodny B, Unterholzner V, Taferner B, et al. Normal kidney size and its influencing factors - a 64-slice MDCT study of 1.040 asymptomatic patients. *BMC Urol.* 2009;9(1):1-13. [[DOI](#)]
9. Palmieri BJ, Petroianu A, Silva LC, Andrade LM, Alberti LR. Estudo do padrão arterial de 200 pedículos renais por meio de angiotomografias. *Rev Col Bras Cir.* 2011;38:116-121. [[DOI](#)]
10. Saldarriaga B, Pinto SA, Ballesteros LE. Morphological expression of the renal artery. A direct anatomical study in a Colombian half-caste population/Expresion morfologica de la arteria renal. Un Estudio Anatomico directo en poblacion mestiza Colombiana. *Int J Morphol.* 2008;26(1):31-39. [[DOI](#)]
11. Garcier JM, De Fraissinette B, Filaire M, et al. Origin and initial course of the renal arteries a radiological study. *Surg Radiol Anat.* 2001;23(1):51-55. [[DOI](#)]
12. Picel AC, Kansal N. Essentials of endovascular abdominal aortic aneurysm repair imaging: preprocedural assessment. *AJR Am J Roentgenol.* 2014;203(4):W347-57. [[DOI](#)]
13. Satyapal KS, Haffejee AA, Singh B, Ramsaroop L, Robbs JV, Kalideen JM. Additional renal arteries incidence and morphometry. *Surg Radiol Anat.* 2001;23(1):33-38. [[DOI](#)]
14. Sampaio FJB, Passos M. Renal arteries: anatomic study for surgical and radiological practice. *Surg Radiol Anat.* 1992;14(2):113-117. [[DOI](#)]
15. Aytac SK, Yigit H, Sancak T, Ozcan H. Correlation Between the Diameter of the Main Renal Artery and the Presence of an Accessory Renal Artery Sonographic and Angiographic Evaluation. *J Med Ultrasound.* 2003;22(5):433-439. [[DOI](#)]